

PATIENT

Luna Hajny

SPECIES

Feline

BREED

ASH

SEX

FS

AGE

8 y

WEIGHT

6 lb

PRESENTING CLINICAL SIGNS

Grade III/VI murmur. BNP 130. Pre-anesthetic evaluation (dental).

ECHOCARDIOGRAPHIC FINDINGS

2D, M-mode, and Doppler study.

Left atrial size is normal. The mitral valve appears normal, though trace mitral regurgitation is present. Left ventricular wall thickness is normal. Left ventricular internal dimensions are normal. Left ventricular systolic function is hyperdynamic. The aorta and aortic valve are normal. Right atrial and right ventricular dimensions are normal. The tricuspid valve appears normal, though mild tricuspid regurgitation is present. The pulmonary artery and pulmonic are normal. No shunting lesions are visualized. No pericardial effusion or cardiac masses are seen.

LA/Ao - 1.32

IVSd - 3.8 mm

LVPWd - 3.7 mm

LVIDd - 12.2 mm

LVIDs - 3.9 mm

FS - 68%

RA - 9.0 mm

LVOT - 0.84 m/s

RVOT - 0.86 m/s

INTERPRETED BY

Keith Blass, DVM, MS,
DACVIM (Cardiology)

IMAGING PERFORMED BY

Karen Ebersole, DVM,
DABVP

HOSPITAL NAME

Scanvet

REFERRING VET

Dr. Cleary

INVOICE

DATE

11/14/25

ASSESSMENT/RECOMMENDATIONS

This examination demonstrates mild regurgitation of blood across Luna's tricuspid valve. The hemodynamic effects of the regurgitation also appear to be mild, as Luna does not have secondary dilation of either of her right heart chambers. As such, Luna's current risk for the development of right-sided congestive heart failure appears to be low.

No therapy is recommended based on this exam.

Luna's cardiovascular risk for general anesthesia appears to be low based on this exam, though I still recommend avoiding the use of alpha-2 agonists in the anesthetic protocol and reducing the IV fluid rate by 25% as precautions. If possible, monitoring of heart rhythm, blood pressure, and pulse oximetry are recommended during the procedure.

A recheck echocardiogram is recommended in 9-12 months, sooner if new clinical signs compatible with cardiac dysfunction develop.



PATIENT

Luna Hajny

SPECIES

Feline

BREED

ASH

SEX

FS

AGE

8 y

WEIGHT

6 lb

INTERPRETED BY

Keith Blass, DVM, MS,
DACVIM (Cardiology)

IMAGING PERFORMED BY

Karen Ebersole, DVM,
DABVP

HOSPITAL NAME

Scanvet

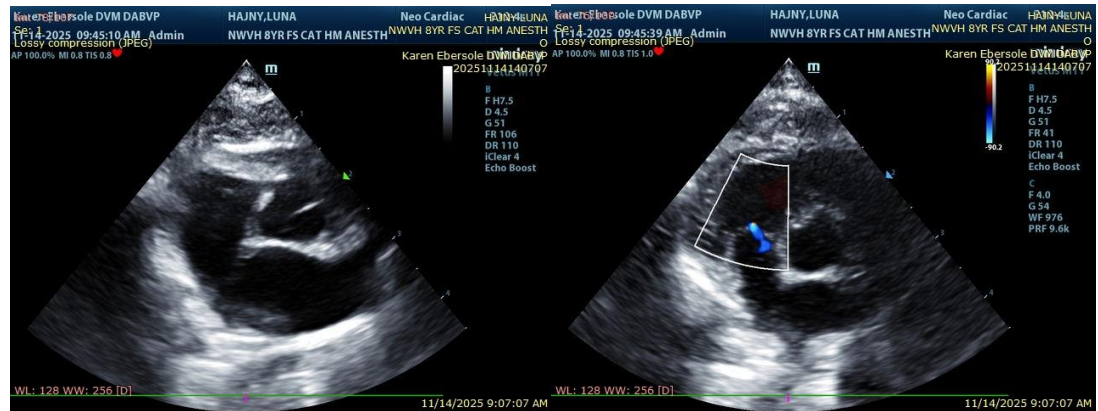
REFERRING VET

Dr. Cleary

INVOICE

DATE

11/14/25



The information and recommendations provided are based on the images presented by the referring veterinarian/sonographer. No evaluation can be communicated regarding pathology that was not visible in the image/video clips provided.

Thank you for this referral. If the clinical or image interpretation does not parallel your findings or if I can be of any further assistance please contact me.

Keith Blass, DVM, MS, DACVIM (Cardiology)

info@SonoPath.com